


PATIENT

Columbus Leon

PRESENTING CLINICAL SIGNS

History: Grade IV/VI heart murmur. Assess prior to anesthesia.

SPECIES

Canine

BREED

Poodle

SEX

Male

AGE

11 years

WEIGHT

14.3lbs

INTERPRETED BY

 Maggie Machen Lamy,
 DVM, DACVIM
 (Cardiology)

IMAGING PERFORMED BY

Jessica Miller

HOSPITAL NAME

 Basking Ridge Animal
 Hospital

REFERRING VET

Dr. Hollo

INVOICE

25932

DATE

8/22/22

ECHOCARDIOGRAM FINDINGS

2D, m-mode, color flow and doppler imaging is available. Diffuse thickening of mitral valve leaflets with mild prolapse into the left atrial lumen. Moderate eccentric mitral regurgitation with mild left atrial dilation. Normal MR velocity. Normal LV diameter with adequate myocardial function. The tricuspid valve appears normal with trace tricuspid regurgitation. Normal velocity. Normal right atrial and ventricular diameter and morphology indicating no overt evidence of pulmonary arterial hypertension. The pulmonic and aortic valves are normal in morphology and mobility. Normal pulmonic and aortic outflow velocities with laminar flow. No obvious aortic or pulmonic insufficiency. No pericardial or pleural effusion noted. No obvious cardiac masses.

CARDIAC CHART

| CANINE CARDIAC PARAMETERS | MR VMAX (m/s) | TR VMAX (m/s) | LA/AO (Boon method) | LA/AO (Heart Base; Swe) | FS (%) | EF (%) | EPSS (cm) |
|---|---------------|---------------|---------------------|-------------------------|---------------------------------|--|--|
| NORMAL PARAMETER | 4.5-5.5 | <2.7 | 1.3 | <1.6 | 28-40 | 40-100 | <0.6 |
| PATIENT | 5.3 | 2.3 | 1.2 | 1.4 | 40 | 72 | 0.2 |
| CANINE CARDIAC PARAMETERS | HR (BPM) | AV VMAX (m/s) | PV MAX (m/s) | BODY WEIGHT (kg) | LA 2D short axis Base view (cm) | LVIDd Avg; 2D and m-mode short axis (cm) | LVIDs Avg; 2D and m-mode short axis (cm) |
| NORMAL PARAMETER | 50-100 | 0.7-1.7 | 0.7-1.6 | BELOW | BELOW | BELOW | BELOW |
| PATIENT | 120 | 1.5 | 1.2 | 6.5 | 2.1 | 3.0 | 1.8 |
| *Normal chamber parameters expressed as a mean value (SD) | | | | 3 | 1.27 (5.3) | 2.46 (2.46) | 1.36 (5.5) |
| BODY WEIGHT DEPENDENT PARAMETERS | | | | 5 | 1.40 (4.5) | 2.74 (5.2) | 1.60 (4.7) |
| <i>*Note: All measurements based upon multi-modal images and methods. An average value is reported.</i> | | | | 10 | 1.50 (3.8) | 3.27 (3.5) | 2.06 (3.1) |
| | | | | 15 | 1.83 (2.0) | 3.71 (2.4) | 2.43 (2.1) |
| | | | | 20 | 2.02 (1.9) | 4.14 (2.2) | 2.80 (2.0) |
| Adapted from June Boon, Veterinary Echocardiography, 1998 | | | | 25 | 2.18 (2.4) | 4.48 (2.9) | 3.10 (2.5) |
| Rishniw M and Hollis NE, J Vet Intern Med 2000; 14:429-435 | | | | 30 | 2.33 (3.3) | 4.83 (3.9) | 3.39 (3.4) |
| Hansson et al, Vet Rad and Ultrasound 2002 | | | | 35 | 2.48 (4.3) | 5.17 (5.0) | 3.69 (4.5) |
| Bonagura et al. Echocardiography: principles of interpretation, Vet Clin North Am 15:1177, 1995 | | | | 40 | 2.62 (5.2) | 5.48 (6.1) | 3.96 (5.4) |
| | | | | 50 | 2.88 (7.1) | 6.07 (8.3) | 4.46 (7.4) |

INTERPRETATION OF THE FINDINGS & FURTHER RECOMMENDATIONS

Chronic degenerative valve disease causing moderate mitral and trace tricuspid regurgitation. Lack of significant left atrial enlargement indicates the current risk for complication is low. No concurrent issues such as systolic dysfunction or pulmonary hypertension are noted in this study.

In an asymptomatic dog with no significant left atrial enlargement, no cardiac medications are clearly indicated. Assessment of progression in the future will help predict long term prognosis, which is highly variable at this stage (B1). Omega fatty acid supplementation and mild salt restriction may be of some long-term benefit. Monitor for development of a cough, labored breathing, exercise intolerance or collapse episodes.



PATIENT

Columbus Leon

SPECIES

Canine

BREED

Poodle

SEX

Male

AGE

11 years

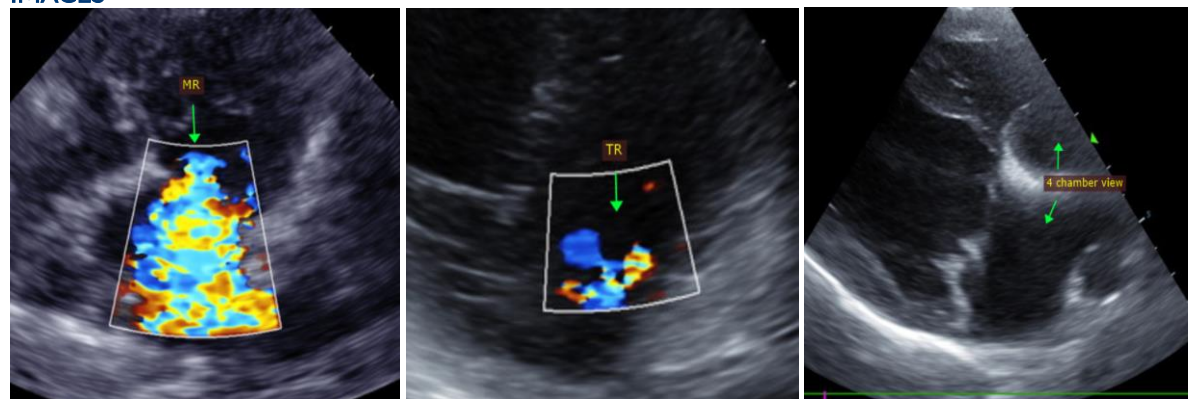
WEIGHT

14.3lbs

Anesthetic risk is considered mild if needed. Cardiac protective drug choices (opioid/benzodiazepine premedication, propofol or alfaxalone induction, isoflurane gas) are recommended. Pre-oxygenate for 5-10 minutes prior to induction. Monitor for arrhythmias, hypotension, and hypoxia both intra and post-operatively and intervene as necessary. Mild IV fluid restriction is recommended to avoid fluid overload. Avoid heart rate stimulating drugs such as atropine unless clinically indicated.

Recommend conservative monitoring with a recheck echocardiogram in 6 months, sooner if any development of clinical signs.

IMAGES



INTERPRETED BY

Maggie Machen Lamy,
DVM, DACVIM
(Cardiology)

The information and recommendations provided are based on the images presented by the referring veterinarian. No evaluation can be communicated regarding pathology that was not visible in the image/video clips provided.

IMAGING PERFORMED BY

Jessica Miller

Thank you for this referral. This report was generated using transcription software, and minor dictation errors may be present. If the clinical or image interpretation does not parallel your findings or if I can be of any further assistance, please contact me.

Maggie Machen Lamy, DVM
Diplomate of the American College of Veterinary Internal Medicine (Cardiology)
info@sonopath.com

HOSPITAL NAME

Basking Ridge Animal
Hospital

REFERRING VET

Dr. Hollo

INVOICE

25932

DATE

8/22/22